Journal of Cranio-Maxillo-Facial Surgery 43 (2015) 34–42

Contents lists available at ScienceDirect

Journal of Cranio-Maxillo-Facial Surgery

journal homepage: www.jcmfs.com

Treatment of condylar fractures with an intraoral approach using an angulated screwdriver: Results of a multicentre study

André Vajgel [a,*], Thiago de Santana Santos [b], Igor Batista Camargo [a], David Moraes de Oliveira [c], José Rodrigues Laureano Filho [a], Ricardo José de Holanda Vasconcellos [a], Sergio Monteiro Lima Jr. [d], Valfrido A. Pereira Filho [e], Andreas A. Mueller [f], Philipp Juergens [f]

[a] University of Pernambuco – School of Dentistry (FOP/UPE), Camaragibe, PE, Brazil
[b] Ribeirão Preto School of Dentistry (FORP/USP), Ribeirão Preto, SP, Brazil
[c] Maurício de Nassau University, Recife, PE, Brazil
[d] Cirurgia Buco-maxilo-facial Hospital das Clínicas, Universidade Federal de Minas Gerais, Belo Horizonte, Brazil
[e] Department of Oral and Maxillofacial Surgery, Dental School of Araraquara/UNESP, Araraquara, Brazil
[f] Dept. of Oral & Maxillofacial Surgery, University Hospital Basel, Faculty of Medicine University of Basel, Basel, Switzerland

ARTICLE INFO

Article history:
Paper received 14 April 2014
Accepted 10 October 2014
Available online 17 October 2014

Keywords:
Intraoral approach
Mandibular condyle
Open treatment

ABSTRACT

Background: This multicentre study aimed to investigate long-term radiographic and functional results following the treatment of condylar fractures using an angulated screwdriver system and open rigid internal fixation with an intraoral surgical approach.
Methods: Twenty-nine patients with a total of 32 condylar fractures were evaluated. The patients were investigated prospectively based on the following variables: age, sex, aetiology, side, location and classification of the fracture, degree of displacement, associated fractures, surgical approach, oral health status, type of osteosynthesis plate, duration of surgery, mouth-opening, complications, and duration of follow-up.
Results: The fractures were classified as subcondylar ($n = 25$) or condylar neck ($n = 7$). Mean patient age was 36.38 ± 16.60 years. The median duration of postoperative follow-up was 24.39 ± 13.94 months. No joint noise, weakness of the facial nerve, joint pain, or muscle pain was observed. An additional retromandibular approach was necessary to enable the treatment of one subcondylar fracture with medial displacement.
Conclusion: Subcondylar or condylar neck fractures with medial or lateral displacement can be treated using an intraoral approach with satisfactory results with the advantages of the absence of visible scarring, the avoidance of facial nerve injury, and the ability to obtain rapid access to the fracture.

1. Introduction

Fractures of the mandibular condyle are common, accounting for 25–35% of all mandibular fractures in reported series (Tasanen and Lamberg, 1976; Ellis et al., 1985). The topic of condylar fracture of the mandible has generated more discussion and controversy than any other issue in the field of maxillofacial trauma with regard to its classification, diagnosis, and therapeutic management (Ellis and Throckmorton, 2005; Ellis, 2009), as evidenced by the various schemes used to classify and subdivide these fractures (Spiessl, 1972; Yamaoka et al., 1994; Choi, 1997; Loukota et al., 2010). A simple classification based on the anatomic location of the fracture (condylar head, condylar neck, subcondylar region) seems adequate (Bos et al., 1999; Loukota et al., 2005), but a concomitant consideration of the degree of fractured segment displacement enriches management decisions (Villarreal et al., 2004; Ellis, 2009).

Mandibular condylar fractures are managed with open or closed treatment, but no consensus has been reached on the proper management of this injury (Hayward and Scott, 1993). The advantages of these two methods must be compared with regard to patient disability, complications, sequelae, and the risks involved (Zide and

* Corresponding author. University of Pernambuco, School of Dentistry – FOP/UPE, Department of Oral and Maxillofacial Surgery, Av. General Newton Cavalcanti, 1650, Tabatinga, 54753-220, Camaragibe, Pernambuco, Brazil. Tel.: +55 81 34582867.
E-mail address: avajgel@hotmail.com (A. Vajgel).

http://dx.doi.org/10.1016/j.jcms.2014.10.006
1010-5182/

Kent, 1983). Despite the suggestion that a prospective randomised trial may not be ethically possible (Bos et al., 1999), there are a few prospective randomised studies that compared closed versus opened treatment (Eckelt et al., 2006; Schneider et al., 2008; Singh et al., 2010). A previous systematic review (Hermund et al., 2008) and a meta-analysis (Nussbaum et al., 2008) attributed the impossibility of performing a reliable meta-analysis to the considerable variation in the reporting of study parameters. Thus, better standardisation of data collection procedures and patient randomisation are necessary for an accurate comparison of the two approaches. As always, however, the patient's best interest takes priority over simple convenience for the surgeon (Villarreal et al., 2004).

Different methods of osteosynthesis are currently used to achieve functionally stable results. A system that enables maximal stability while causing minimal trauma during insertion should be selected. Moreover, easy handling increases surgeons' acceptance of a procedure (Pilling et al., 2010). The intraoral approach is not routinely used for the treatment of subcondylar fractures because the management of dislocated fractures may be hampered by the limited visibility of the fracture site due to the location of the coronoid process. However, intraoral treatment can be facilitated by the use of endoscopic techniques with angulated scopes (Jacobovicz et al., 1998; Chen et al., 1999; Lauer and Schmelzeisen, 1999; Schon et al., 2003; Kokemueller et al., 2011). Clinical mirrors have also been used to check posterior border reduction and fixation (Pereira-Filho et al., 2011). The recent introduction of an angulated screwdriver system makes the use of the intraoral approach for the treatment of displaced subcondylar or condylar neck fractures feasible without the need for endoscopic instruments or mirrors.

The purpose of the present study was to assess the long-term outcomes of the open reduction of condylar fractures managed through an intraoral approach using an angulated screwdriver system and open rigid internal fixation.

2. Material and methods

Thirty consecutive patients (10 from each of the three departments: University of Pernambuco, Dental School of Araraquara/UNESP and University Hospital Basel) who were diagnosed with subcondylar fractures, with or without other associated mandibular fractures, and treated between 2008 and 2010 were included in this study. One patient with a combination of subcondylar and condylar head fracture was excluded, because the condylar head fracture could influence the clinical result. Therefore, 29 patients [21 male, eight female; mean age, 36.38 years; standard deviation (SD), 16.60 years] with a total of 32 condylar fractures (25 subcondylar and seven condylar neck) were evaluated. All subcondylar and condylar neck fractures were treated with an intraoral surgical approach and fixation with trapezoidal or straight plates using an angulated screwdriver system (MODUS; Medartis, Basel, Switzerland; Fig. 1) without endoscopic assistance. However, one subcondylar fracture with medial displacement required a retromandibular approach for reduction and fixation.

In all cases, computed tomography (CT) was used to detect fragment positions in the preoperative and postoperative periods. The following variables were recorded: age, sex, aetiology, side, location and classification of the fracture, degree of displacement, associated fractures, surgical approach, duration of surgery, complications, and duration of follow-up (Table 1).

2.1. Surgical approach

Under general anaesthesia, a local anaesthetic with a vasoconstrictor was injected at the anterior border of the mandibular ramus. Access was achieved in a manner similar to that used for sagittal osteotomy, with greater posterosuperior extension. The buccinator muscle and periosteum were incised by monopolar diathermy. The temporal muscle was detached from the anterior border of the mandibular ramus and the subjacent periosteum was detached from the masseter muscle, which was carefully dissected from the lateral surface of the mandible. Sufficient space was created to provide adequate access and enable passive placement of the retractors. Ramus retractors were then positioned to embrace the posterior border of the ramus, thereby providing an adequate field for the reduction of the subcondylar fracture.

Following fracture reduction, intermaxillary fixation (IMF) was performed with stainless-steel wire or heavy elastics and the fragments were aligned anatomically. The plates were fixed with the aid of an angulated screwdriver (Fig. 2). For this procedure, a perforation was made in the proximal segment and the plate was placed together with a screw adhering to the angulated screwdriver. Following the fixation of the first screw, the second screw was also fixed in the proximal segment. Fixation of the plate in the proximal segment allowed better handling, and pulling the plate with a hook facilitated fracture reduction. Screws were then fixed in the distal segment. The maxillomandibular fixing was removed, occlusion was checked, and the soft tissues were sutured (Fig. 3).

If necessary, the IMF screws and elastic bands can be used for postoperative exercises. However, this procedure was not performed in any of the present cases. In the patient with a condylar head fracture, an orthodontic appliance was installed after surgery and used for elastic band treatment in the postoperative period.

2.2. Clinical examination

The goal of treatment was the restoration of correct occlusion and mandibular kinetics as close to normal as possible. Patients

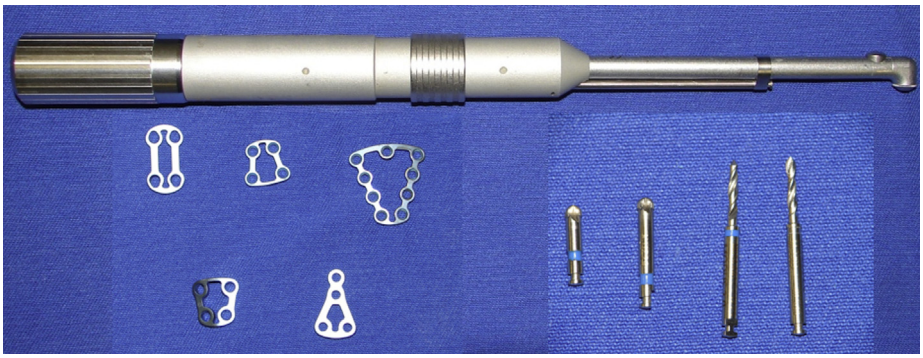

Fig. 1. Angulated screwdriver system and trapezoidal condylar plates.

returned 7 and 15 days and 1, 4, and 6 months postoperatively for regular check-ups and monitoring for any irregular clinical symptoms. Occlusion and bone healing were checked with x-rays and CT scans. The clinical outcome indices were temporomandibular joint (TMJ) function (range of mouth opening and deviation), occlusion, signs/symptoms of infection, soft-tissue dehiscence/plate exposure, non-union/mobility of segments, and plate/screw loosening. Occlusion was monitored carefully by evaluating intercuspation and maximal interincisal opening, as well as mandibular protrusion and excursive movement. Patients were also observed carefully to detect any noise (clicking) or pain in the TMJ.

3. Results

Patients' profiles, trauma aetiology, fracture characteristics (classification), side and degree of displacement, surgical approach, associated fractures, surgery time, complications, and follow-up duration are presented in Table 1. The mean patient age was 36.38 ± 16.60 years. The aetiologies of injury were: a traffic accident in 10 patients; physical aggression in eight; a fall from stairs, standing or sitting height in four; cycling in three; horse riding in two and a sporting accident in two. Subcondylar and condylar neck fractures occurred on the right side in 17 and five cases and on the left side in eight and two cases, respectively. Displacement of the subcondylar and condylar neck fractures was observed on the lateral side in 21 and four cases, and on the medial side in four and three cases, respectively. Fifteen patients had isolated mandibular condylar fractures, and 14 had additional mandibular fractures. Most fractures were linear, which facilitated reduction and fixation via a transoral approach; patient 5 had a comminuted fracture that was very challenging to treat using this approach (Fig. 5).

The fractures were classified as subcondylar ($n = 25$) or condylar neck ($n = 7$). Most fractures were treated via an intraoral approach. In contrast, patient 6 had a medially displaced left subcondylar fracture for which attempted reduction via an intraoral approach was not successful; thus, an additional retromandibular approach was used (Fig. 4).

Patient 23 had a loose plate after 10 weeks without complications and in one patient a haematoma was intraorally evacuated under local anaesthesia. The median duration of postoperative follow-up was 24.39 ± 13.94 months. No signs or symptoms of infection, soft-tissue dehiscence/plate exposure, non-union/mobility of segments, occlusal change, joint noise, weakness of the facial nerve, joint pain, or muscle pain were observed. Most patients showed limitations of mandibular movement, such as mouth opening and lateral excursion, during the first month postoperatively. These patients underwent active physical therapy and the range of mandibular movements increased gradually. At 6 months postoperatively, all patients showed a satisfactory range of mandibular movement with (mean ± SD) 45.83 ± 3.8; 10.5 ± 1.57; 9.42 ± 1.12; and 8.75 ± 1.09 mm for mouth opening, protrusion and lateroprotrusion to the right and left side, respectively (Table 1).

4. Discussion

Despite advances in the management of condylar fractures, the indication for open treatment remains a topic of discussion and several attempts to reach consensus have been made (Baker et al., 1998; Bos et al., 1999). Agreement has been reached that displaced bilateral fractures or severe unilateral displacement in the condylar neck or subcondylar region (except in growing children) may be indications for open reduction and internal fixation (ORIF) (Zide and Kent, 1983; Ellis, 2009). ORIF is recommended in such cases because it can achieve better, more rapid functional rehabilitation of the TMJ; indeed, superior clinical functional results have been reported in some prospective randomised studies when compared with closed treatment (Eckelt et al., 2006; Schneider et al., 2008; Singh et al., 2010). Furthermore, such injuries may cause temporomandibular or occlusal disorders, TMJ ankylosis, compromised ramus height, and mandibular deviation if not properly treated, and may lead to severe impairment of the stomatognathic system (Ellis and Throckmorton, 2005; Veras et al., 2007).

Extraoral approaches continue to be used more widely than intraoral approaches for the treatment of condylar fractures. However, the development of specialised instruments, such as reduction forceps, angulated elevators, long periosteal elevators and retractors, modified nerve hooks, the angulated screwdriver system and endoscopes, has facilitated the reduction and fixation of such fractures. These instruments have increased the feasibility of the intraoral approach in the treatment of fractures of the mandibular condyle. The therapeutic success of this approach depends mainly on proper fragment reduction (Mokros and Erle, 1996). Others (Handschel et al., 2012) evaluated the outcome of different treatment approaches regarding function and surgical side-effects. The study concluded that subcondylar fractures benefit from ORIF by an intraoral approach, whereas in condylar neck fractures the retromandibular/transparotid approach shows the best results. However, a small number of condylar neck fractures have been treated by an intraoral approach in our study and we achieved adequate results. The necessity and benefit of endoscopic assistance for intraoral ORIF of mandibular condylar fractures remain unclear (Kanno et al., 2011). Kanno et al. (2011) successfully treated 15 linear subcondylar fractures using an intraoral approach and a small angulated screwdriver system with no endoscopic assistance, and found that this treatment method was safe and minimally invasive and produced reliable clinical results.

In surgical approaches to ORIF for fractures of the condylar process, access differs between condylar neck and subcondylar fractures due to the inability to visualise the fracture directly through an intraoral incision, according to the classification proposed by Ellis (Ellis, 2009). In contrast, the subcondylar area is typically well visualised using instruments such as Bauer and Merrill-Lavasseur retractors, followed by anatomic reduction with rigid internal fixation under direct viewing with the aid of a small angulated screwdriver, as described here (Kitagawa et al., 2004; Kanno et al., 2010, 2011; Vajgel et al., 2013). Thus, the results of the present study indicate that the relationship of the fracture to the sigmoid notch is a useful metric that can be applied to determine the feasibility of intraoral condyle management; fractures that extend posteriorly below the sigmoid notch are transorally visualised more readily than those that do not extend below the notch.

Similar to the findings in previous reports (Kitagawa et al., 2004; Veras et al., 2007), immediate functional recovery was established in the present series of 32 subcondylar and condylar neck fractures, with good medium-term clinical results. Although this surgery may seem to be technically difficult and to depend on experience, Kanno et al. (2011) found no significant difference in operative time between an experienced maxillofacial trauma surgeon and residents training in oral and maxillofacial surgery, although surgical duration may not be as important as the clinical results and visibility during surgery. The maximum and minimum durations of surgery in the present series were 125 and 35 min, respectively. The mean operative time (70.48 ± 24.37 min) was longer than that reported in a similar previous study (52.2 min) (Kanno et al., 2011) However, this difference was attributed to two cases in the present series: patient 6 had a medially displaced left subcondylar fracture that could not be reduced via an intraoral approach and required an additional retromandibular approach; and patient 5 had a

Table 1
Description of mandibular subcondylar fractures in 29 patients.

Patient	Fracture no	Age (y)	Sex	Aetiology	Condylar fracture classification	Side	Displacement	Approach	Associated fracture	Type of osteosynthesis plate	Oral health status	Condylar fracture operative time (min)	Complications	Mouth-opening 6 months after surgery [mm]	Protrusion 6 months after surgery [mm]	Laterotrusion 6 months after surgery [mm] R/L	Follow-up
1	1	49	F	Motorcycle accident	Subcondylar	R	Lateral	Intraoral	Body (R)	2.0 mm 4-hole trapezoidal locking plate	Partially dentate – IMF with prosthesis	85	–	47	11.5	8.5/7.5	48
2	2	30	F	Sports accident	Subcondylar	L	Lateral	Intraoral	–	2.0 mm 4-hole trapezoidal locking plate	Dentate	70	–	46	9.5	8.5/8	38
3	3	43	M	Car accident	Subcondylar	R	Lateral	Intraoral	Body (L)	2.0 mm 4-hole trapezoidal locking plate	Dentate	80	–	48	10	9/9.5	32
4	4	41	M	Physical aggression	Subcondylar	L	Lateral	Intraoral	–	2.0 mm 4-hole delta locking plate	Dentate	90	–	43	7.5	8/8	20
5	5	41	M	Physical aggression	Subcondylar	R	Lateral	Intraoral	Ramus + angle (R)	2.0 mm 4-hole trapezoidal locking plate	Dentate	125	–	45	10	10/9.5	14
6	6	27	M	Motorcycle accident	Subcondylar	R	Lateral	Intraoral	Body (R)	2.0 mm 4-hole delta locking plate	Dentate	75 (R)	–	47	9	8.5/9.5	10
	7				Subcondylar	L	Medial	Intraoral + retromandibular		2.0 mm 4-hole trapezoidal locking plate		135 (L)					
7	8	43	F	Horse riding accident	Subcondylar	L	Lateral	Intraoral	-	2.0 mm 4-hole-plate + 2.0 mm 2-hole-plate	Dentate	90	–	42	8	6/8	42
8	9	30	M	Cycling accident	Subcondylar	R	Lateral	Intraoral	Symphysis	2.0 mm 4-hole-plate + 2.0 mm 2-hole-plate	Dentate	95	–	44	7	7.5/7	40
9	10	82	M	Fall from standing height	Subcondylar	R	Lateral	Intraoral	–	2.0 mm 4-hole-plate + 2.0 mm 2-hole-plate	Edentulous- IMF with prothesis	75	–	46	8.5	8.5/8.5	36
10	11	24	F	Sports accident	Subcondylar	R	Medial	Intraoral	–	2.0 mm 4-hole-plate + 2.0 mm 2-hole-plate	Dentate	60	–	39	6	6.5/6	32
11	12	19	M	Physical aggression	Subcondylar	R	Lateral	Intraoral	–								
12	13	26	M	Physical aggression	Subcondylar	R	Lateral	Intraoral	–	2.0 mm 4-hole-plate + 2.0 mm 2-hole-plate	Dentate	45	–	48	11	9.5/9	26
13	14	60	F	Fall from standing height	Condylar Neck	R	Medial	Intraoral	–	2.0 mm 4-hole trapezoidal locking plate	Edentulous – IMF with prosthesis	75	–	41	10	8/7	26
14	15	23	M	Cycling accident	Subcondylar	R	Lateral	Intraoral	Symphysis	2.0 mm 4-hole trapezoidal locking plate	Dentate	55	–	47	12	10.5/9.5	22
15	16	19	M	Physical aggression	Subcondylar	R	Lateral	Intraoral	–	2.0 mm 4-hole trapezoidal locking plate	Dentate	60	–	47	11	10/9	20

(*continued on next page*)

Table 1 (*continued*)

Patient	Fracture no	Age (y)	Sex	Aetiology	Condylar fracture classification	Side	Displacement	Approach	Associated fracture	Type of osteosynthesis plate	Oral health status	Condylar fracture operative time (min)	Complications	Mouth-opening 6 months after surgery [mm]	Protrusion 6 months after surgery [mm]	Laterotrusion 6 months after surgery [mm] R/L	Follow-up
16	17	16	F	Cycling accident	Condylar Neck	R	Lateral	Intraoral	–	2.0 mm 4-hole trapezoidal locking plate	Dentate	40	–	41	10	9.5/9	20
17	18	28	M	Car accident	Subcondylar	R	Lateral	Intraoral	Body (L)	2.0 mm 4-hole-plate + 2.0 mm 2-hole-plate	Dentate	45	–	48	9	9/9.5	18
18	19	24	M	Physical aggression	Subcondylar	L	Medial	Intraoral	Parasymphyseal (L)	2 × 2.0 mm 4-hole-plate	Dentate	60	Haematoma to be intraorally evacuated under local anaesthesia	46	9	9.5/8.5	16
19	20	53	M	Car accident	Condylar Neck	R	Medial	Intraoral	Angle (L)	2.0 mm 4-hole trapezoidal locking plate	Dentate	65	–	49	10	1010.5	12
20	21	14	F	Horse riding accident	Subcondylar	L	Lateral	Intraoral		2.0 mm 4-hole trapezoidal locking plate	Dentate	75	–	45	9	9/8.5	27
21	22	66	F	Fall from stairs	Subcondylar	R	Lateral	Intraoral		2.0 mm 4-hole trapezoidal locking plate	Maxilla edentolous, mandible partially edentolous	75	–	35	7	6.5/7	6
	23				Condylar Neck	L	Lateral	Intraoral		2.0 mm 4-hole-plate + 2.0 mm 2-hole-plate		35	Plate loosening after 10 weeks				
22	24	62	M	Fall from sitting height	Subcondylar	R	Lateral	Intraoral		2.0 mm 4-hole trapezoidal locking plate	Partially edentolous	35	-	46	9	9/8.5	6
	25				Subcondylar	L	Medial	Intraoral		2.0 mm 4-hole dalta-shape locking plate		60	-				
23	26	54	M	Motor Cycle accident	Subcondylar	R	Lateral	Intraoral	Body (L)	2.0 mm 4-hole trapezoidal locking plate	Dentate	40	-	43	9	9/8	10
24	27	28	M	Car accident	Condylar Neck	R	Lateral	Intraoral	Body (L)	2.0 mm 4-hole-plate + 2.0 mm 2-hole-plate	Dentate	35	-	52	12	9.5/9	10
25	28	24	M	Physical aggression	Condylar Neck	L	Lateral	Intraoral	Para-symphyseal (L)	2.0 mm 4-hole-plate + 2.0 mm 4-hole-plate	Dentate	60	-	48	12	9.5/9	9
26	29	36	M	Car accident	Subcondylar	L	Lateral	Intraoral	Parasynphysal (R)	2.0 mm 5 hole plate	Dentate	80	-	53	11	10/9	36
27	30	32	M	Motorcycle accident	Subcondylar	R	Lateral	Intraoral	Synphysal	2.0 mm TCP plate	Partially Dentate	90	-	43	9.5	9/9.5	60
28	31	29	M	Motorcycle accident	Subcondylar	R	Lateral	Intraoral		2.0 mm TCP plate	Partially Dentate	80	-	44	10	9.5/8.5	36
29	32	32	M	Physical aggression	Condylar Neck	R	Medial	Intraoral	–	2.0 mm 5 hole large profile unilock plate	Dentate	95	-	49	11	9.5/10.5	11

F: female; L: left; m: month; M: male; R: right; y: year.

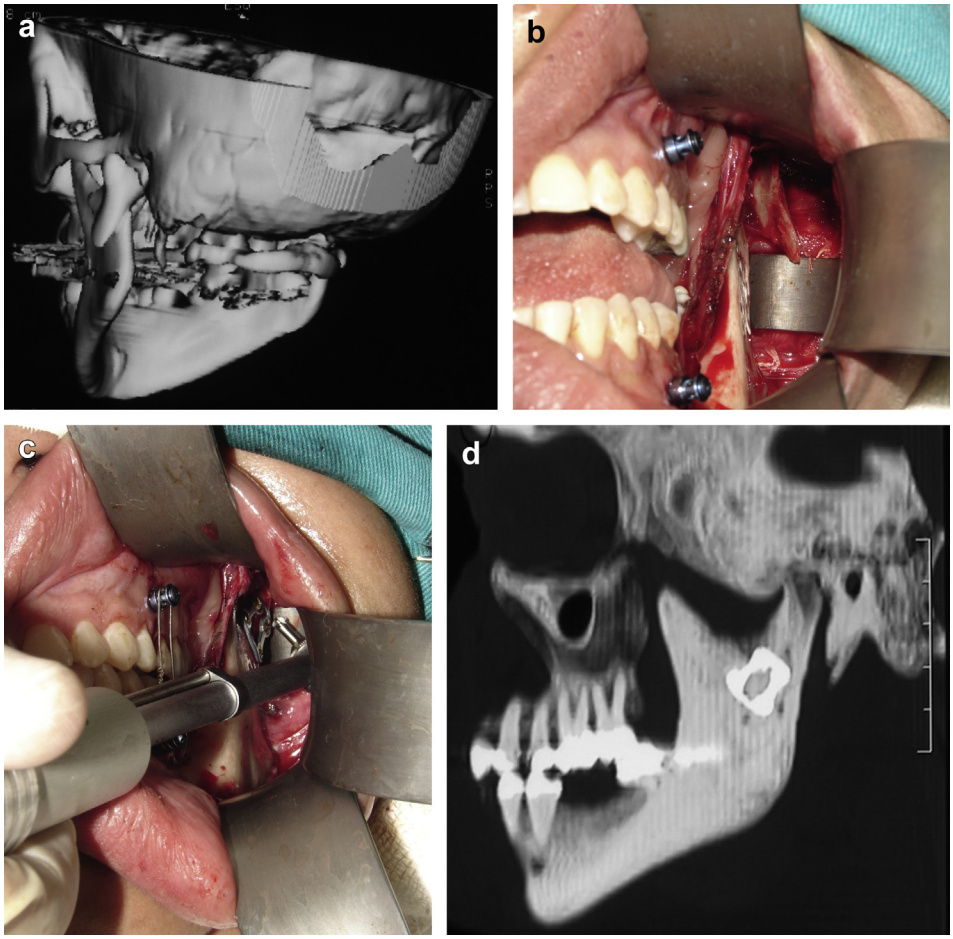

Fig. 2. Patient 2. a) Preoperative three-dimensional computed tomographic images showing the left subcondylar fracture with lateral displacement; b) Clinical view of the fracture and use of Bauer and Merrill-Lavasseur retractors; c) A trapezoidal condylar plate was fixed with an angulated screwdriver using an intraoral approach; d) Postoperative computed tomographic image showing satisfactory reduction of the subcondylar fracture.

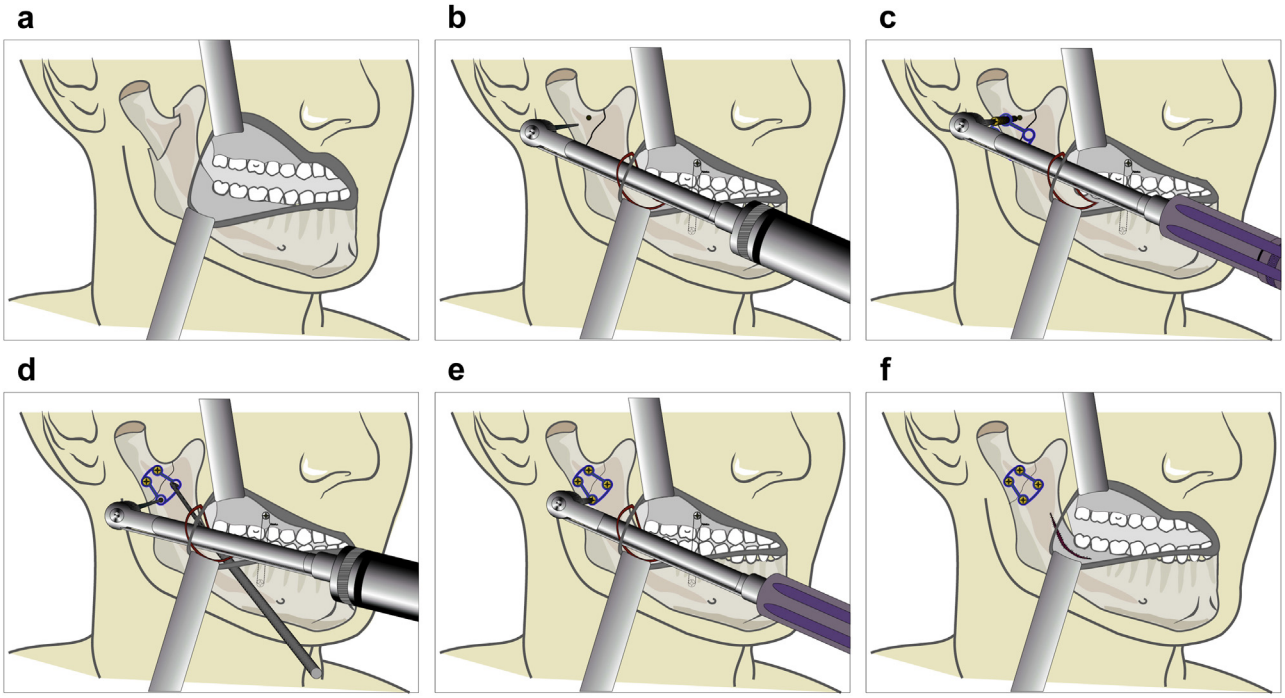

Fig. 3. Description of the surgical technique. a) Subcondylar fracture; b) Intermaxillary fixation and perforation of the proximal segment; c) Fixation of the trapezoidal condylar plate with the first screw; d) After fixation of the second screw, a minihook was used to reduce the fracture by pulling the plate against the distal segment; e) Fixation of two screws in the distal segment; f) Occlusion was checked and intermaxillary fixation screws were removed before wound closure.

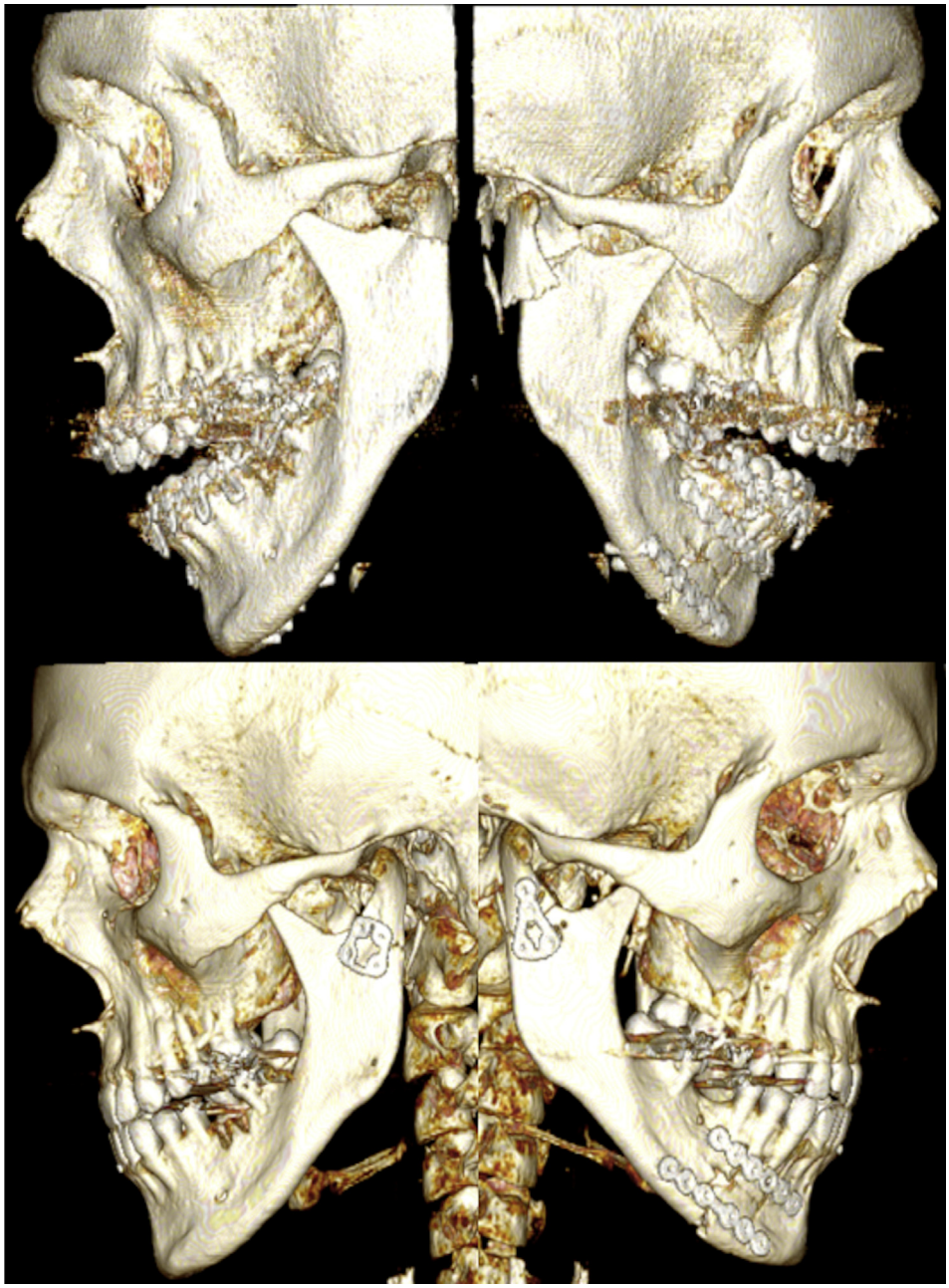

Fig. 4. Patient 6. Preoperative three-dimensional computed tomographic image showing anterior open bite, bilateral subcondylar fractures with lateral (right) and medial (left) displacement, and a right body fracture treated by another surgeon. Postoperative three-dimensional computed tomographic image showing adequate reduction of the bilateral subcondylar fractures; the left fracture was reduced and fixed via a retromandibular approach after a failed reduction attempt using an intraoral approach.

comminuted subcondylar fracture that required a longer operative time to treat than a linear fracture.

Previous clinical and biomechanical studies have recommended the use of two miniplates for fixation when treating a condylar fracture using the intraoral approach: the first miniplate is placed on the axis of the condylar neck and the second is placed obliquely under the mandibular notch (Schon et al., 2003; Meyer et al., 2006; Pilling et al., 2010). This technique complies with the principles of osteosynthesis regarding functional stability, and significantly better results have been reported (Meyer et al., 2008). However, the positioning of four screws in the proximal condylar fragment is sometimes difficult due to its small size, and this technique is nearly impossible to employ in cases of condylar neck fracture (Meyer et al., 2008; Pereira-Filho et al., 2011). A trapezoidal condylar plate (TCP), or compression miniplate, can be used in place of the two miniplates (Meyer et al., 2008). The aims of TCPs are to comply with the principles of functionally stable osteosynthesis proposed in the 1970s (Champy et al., 1976) and to take advantage of the three-dimensional characteristics of the plate, as established in the 1990s (Farmand, 1996). TCPs offer enhanced stability and the possibility of osteosynthesis of small fragments, and require less periosteal dissection (Farmand, 1996). The use of these plates has achieved excellent experimental (Meyer et al., 2007) and clinical (Meyer et al., 2008) results.

Several studies have evaluated the long-term outcomes of ORIF for mandibular condylar fractures using an intraoral approach

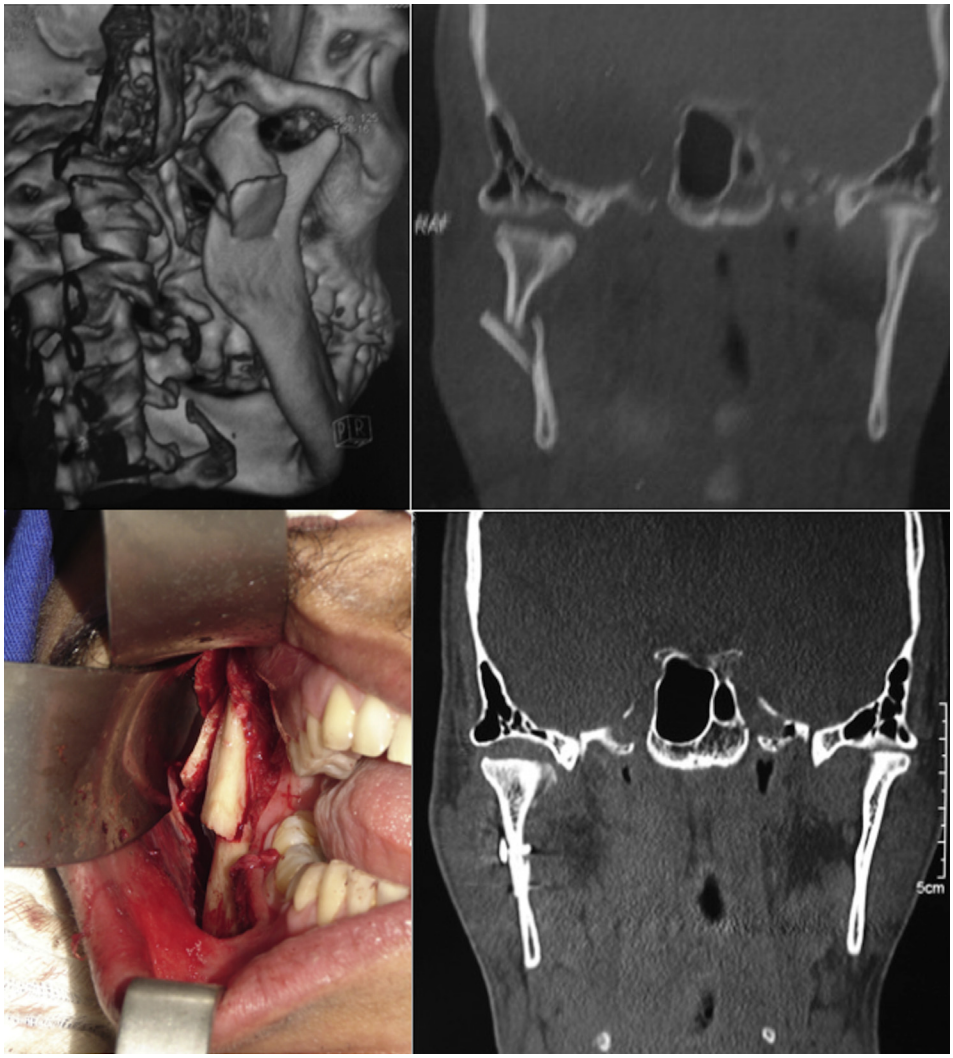

Fig. 5. Patient 5: the comminuted subcondylar fracture was reduced using an intraoral approach.

(Jacobovicz et al., 1998; Chen et al., 1999; Lauer and Schmelzeisen, 1999; Schon et al., 2002, 2003; Veras et al., 2007; Kanno et al., 2011; Kokemueller et al., 2011; Pereira-Filho et al., 2011). Some surgeons have employed endoscopic-assisted procedures (Jacobovicz et al., 1998; Chen et al., 1999; Lauer and Schmelzeisen, 1999; Schon et al., 2002, 2003; Veras et al., 2007; Kokemueller et al., 2011), whereas others have used only an angulated screwdriver and clinical mirrors (Kanno et al., 2011; Pereira-Filho et al., 2011). In the former, the use of an endoscope allows superior visibility of the condylar area, thereby overcoming the problem of limited exposure through limited incisions (Schneider et al., 2007). However, other studies reported no difference between the two techniques (Schon et al., 2002). For both techniques, a learning curve with intensive training is necessary before the treatment of condylar fractures can be performed consistently using an intraoral approach.

As in a similar previous study (Kanno et al., 2011), the present sample was small and non-homogeneous, including unilateral and bilateral condylar fractures combined with additional mandibular fractures. Further studies, the accumulation of more cases with a longer follow-up period, and intensive clinical investigation are recommended. Nonetheless, the small angulated screwdriver appears to be an important new device that is beneficial and efficient in less-invasive maxillofacial surgery, which is advantageous for the clinical outcome.

5. Conclusion

In summary, subcondylar or condylar neck fractures with medial or lateral displacement can be treated using an intraoral approach with satisfactory results. The advantages of this approach are the absence of visible scarring, the avoidance of facial nerve injury that could occur with an extraoral approach, and the provision of rapid access to the fracture.

References

Baker AW, McMahon J, Moos KF: Current consensus on the management of fractures of the mandibular condyle. A method by questionnaire. Int J Oral Maxillofac Surg 27: 258–266, 1998

Bos RR, Ward Booth RP, de Bont LG: Mandibular condyle fractures: a consensus. Br J Oral Maxillofac Surg 37: 87–89, 1999

Champy M, Lodde JP, Jaeger JH, Wilk A: Mandibular osteosynthesis according to the Michelet technic. I. Biomechanical bases. Rev Stomatol Chir Maxillofac 77: 569–576, 1976

Chen CT, Lai JP, Tung TC, Chen YR: Endoscopically assisted mandibular subcondylar fracture repair. Plast Reconstr Surg 103: 60–65, 1999

Choi BH: Magnetic resonance imaging of the temporomandibular joint after functional treatment of bilateral condylar fractures in adults. Int J Oral Maxillofac Surg 26: 344–347, 1997

Eckelt U, Schneider M, Erasmus F, Gerlach KL, Kuhlisch E, Loukota R, et al: Open versus closed treatment of fractures of the mandibular condylar process: a prospective randomized multi-centre study. J Craniomaxillofac Surg 34: 306–314, 2006

Ellis 3rd E: Method to determine when open treatment of condylar process fractures is not necessary. J Oral Maxillofac Surg 67: 1685–1690, 2009
Ellis E, Throckmorton GS: Treatment of mandibular condylar process fractures: biological considerations. J Oral Maxillofac Surg 63: 115–134, 2005
Ellis 3rd E, Moos KF, el-Attar A: Ten years of mandibular fractures: an analysis of 2,137 cases. Oral Surg Oral Med Oral Pathol 59: 120–129, 1985
Farmand M: Experiences with the 3-D miniplate osteosynthesis in mandibular fractures. Fortschr Kiefer Gesichtschir 41: 85–87, 1996
Handschel J, Ruggeberg T, Depprich R, Schwarz F, Meyer U, Kubler NR, et al: Comparison of various approaches for the treatment of fractures of the mandibular condylar process. J Craniomaxillofac Surg 40: e397–401, 2012
Hayward JR, Scott RF: Fractures of the mandibular condyle. J Oral Maxillofac Surg 51: 57–61, 1993
Hermund NU, Hillerup S, Kofod T, Schwartz O, Andreasen JO: Effect of early or delayed treatment upon healing of mandibular fractures: a systematic literature review. Dent Traumatol 24: 22–26, 2008
Jacobovicz J, Lee C, Trabulsy PP: Endoscopic repair of mandibular subcondylar fractures. Plast Reconstr Surg 101: 437–441, 1998
Kanno T, Mitsugi M, Sukegawa S, Fujioka M, Furuki Y: Submandibular approach through the submandibular gland fascia for treating mandibular fractures without identifying the facial nerve. J Trauma 68: 641–643, 2010
Kanno T, Sukegawa S, Fujioka M, Takabatake K, Furuki Y: Transoral open reduction with rigid internal fixation for subcondylar fractures of the mandible using a small angulated screwdriver system: is endoscopic assistance necessary? J Oral Maxillofac Surg 69: e372–384, 2011
Kitagawa Y, Sano K, Nakamura M, Miyauchi K: Transoral osteosynthesis at the mandibular ramus and subcondyle using angular screwing instrument and biodegradable miniplate system. J Oral Maxillofac Surg 62: 1041–1043, 2004
Kokemueller H, Konstantinovic VS, Barth EL, Goldhahn S, von See C, Tavassol F, et al: Endoscope-assisted transoral reduction and internal fixation versus closed treatment of mandibular condylar process fractures: a prospective Double-Center study. J Oral Maxillofac Surg 70(2): 384–395, 2011
Lauer G, Schmelzeisen R: Endoscope-assisted fixation of mandibular condylar process fractures. J Oral Maxillofac Surg 57: 36–39, 1999 discussion 39–40
Loukota RA, Eckelt U, De Bont L, Rasse M: Subclassification of fractures of the condylar process of the mandible. Br J Oral Maxillofac Surg 43: 72–73, 2005
Loukota RA, Neff A, Rasse M: Nomenclature/classification of fractures of the mandibular condylar head. Br J Oral Maxillofac Surg 48: 477–478, 2010
Meyer C, Martin E, Kahn JL, Zink S: Development and biomechanical testing of a new osteosynthesis plate (TCP) designed to stabilize mandibular condyle fractures. J Craniomaxillofac Surg 35: 84–90, 2007
Meyer C, Serhir L, Boutemi P: Experimental evaluation of three osteosynthesis devices used for stabilizing condylar fractures of the mandible. J Craniomaxillofac Surg 34: 173–181, 2006
Meyer C, Zink S, Chatelain B, Wilk A: Clinical experience with osteosynthesis of subcondylar fractures of the mandible using TCP plates. J Craniomaxillofac Surg 36: 260–268, 2008
Mokros S, Erle A: Transoral miniplate osteosynthesis of mandibular condyle fractures–optimizing the surgical method. Fortschr Kiefer Gesichtschir 41: 136–138, 1996
Nussbaum ML, Laskin DM, Best AM: Closed versus open reduction of mandibular condylar fractures in adults: a meta-analysis. J Oral Maxillofac Surg 66: 1087–1092, 2008
Pereira-Filho V, Welsh B, Schübel F, Landes C, Sader R, Gabrielli M, et al: Intraoral approach for treatment of displaced condylar fractures: case report. Craniomaxillofac Trauma Reconstr 4: 107–111, 2011
Pilling E, Eckelt U, Loukota R, Schneider K, Stadlinger B: Comparative evaluation of ten different condylar base fracture osteosynthesis techniques. Br J Oral Maxillofac Surg 48: 527–531, 2010
Schneider M, Erasmus F, Gerlach KL, Kuhlisch E, Loukota RA, Rasse M, et al: Open reduction and internal fixation versus closed treatment and mandibulomaxillary fixation of fractures of the mandibular condylar process: a randomized, prospective, multicenter study with special evaluation of fracture level. J Oral Maxillofac Surg 66: 2537–2544, 2008
Schneider M, Lauer G, Eckelt U: Surgical treatment of fractures of the mandibular condyle: a comparison of long-term results following different approaches – functional, axiographical, and radiological findings. J Craniomaxillofac Surg 35: 151–160, 2007
Schon R, Gutwald R, Schramm A, Gellrich NC, Schmelzeisen R: Endoscopy-assisted open treatment of condylar fractures of the mandible: extraoral vs intraoral approach. Int J Oral Maxillofac Surg 31: 237–243, 2002
Schon R, Schramm A, Gellrich NC, Schmelzeisen R: Follow-up of condylar fractures of the mandible in 8 patients at 18 months after transoral endoscopic-assisted open treatment. J Oral Maxillofac Surg 61: 49–54, 2003
Singh V, Bhagol A, Goel M, Kumar I, Verma A: Outcomes of open versus closed treatment of mandibular subcondylar fractures: a prospective randomized study. J Oral Maxillofac Surg 68: 1304–1309, 2010
Spiessl B: Rigid internal fixation of fractures of the lower jaw. Reconstr Surg Traumatol 13: 124–140, 1972
Tasanen A, Lamberg MA: Transosseous wiring in the treatment of condylar fractures of the mandible. J Maxillofac Surg 4: 200–206, 1976
Vajgel A, de Santana Santos T, Camargo IB, Moraes de Oliveira D, Filho JR, de Holanda Vasconcellos RJ: Management of subcondylar fracture by intraoral approach. J Craniofac Surg 24: 587–588, 2013
Veras RB, Kriwalsky MS, Eckert AW, Schubert J, Maurer P: Long-term outcomes after treatment of condylar fracture by intraoral access: a functional and radiologic assessment. J Oral Maxillofac Surg 65: 1470–1476, 2007
Villarreal PM, Monje F, Junquera LM, Mateo J, Morillo AJ, Gonzalez C: Mandibular condyle fractures: determinants of treatment and outcome. J Oral Maxillofac Surg 62: 155–163, 2004
Yamaoka M, Furusawa K, Iguchi K, Tanaka M, Okuda D: The assessment of fracture of the mandibular condyle by use of computerized tomography. Incidence of sagittal split fracture. Br J Oral Maxillofac Surg 32: 77–79, 1994
Zide MF, Kent JN: Indications for open reduction of mandibular condyle fractures. J Oral Maxillofac Surg 41: 89–98, 1983